

Laminitis case in 2004:

ANGEL



Laminitis history for Angel



DECEMBER 1994 Angel, 7 months, takes in her new surroundings at Three Creek Farm after arriving from Arizona.



APRIL 1998 Angel, age 4, is severely overweight at a dressage schooling show at Bridlespur. In November 1998, she moved to Ohio on a lease. Over the next three years, she had two foals and stayed at a more appropriate weight.



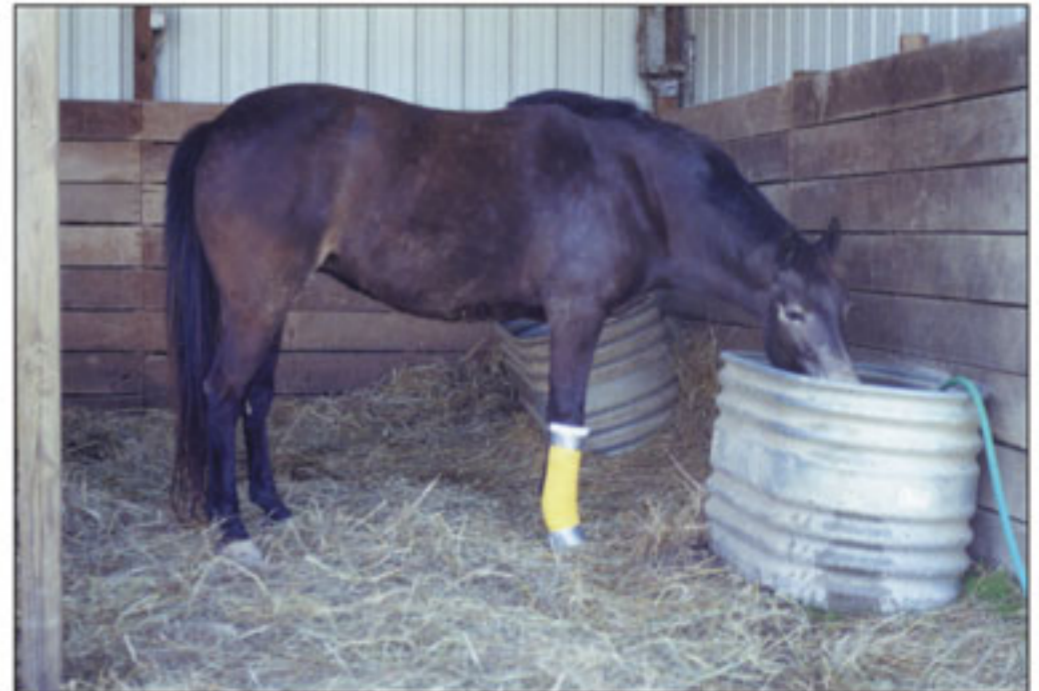SEPTEMBER 1996 Angel, age 2, fits in a men's extra large sweatshirt, or two of them, for a holiday card. She was growing up, not out, and didn't have an ounce of fat on her.



OCTOBER 2001 Angel, age 7, is very thin after suffering an acute case of enteritis in September 2001, right before she was supposed to leave Ohio for home. With outstanding care, she managed to pull through. She lost a lot of weight but did not stay thin for long.



SPRING 1997 Angel, age 3, attends a SLADS dressage show at the Bridlespur Hunt Club in June 1997. She looked in excellent form. She moved to Kerrymor Farm in August 1997 and was put with three siblings she had not lived with before. Hay was used as a peacekeeper. Everyone expanded.



APRIL 2003 Angel, age 9, drinks water from her trough after returning home from Mizzou, where she had surgery to remove a bone chip. She was heavy enough to prompt the surgeons to ask if she had ever foundered. She came home a better weight and stayed that way through the fall.

Laminitis history for Angel



JAN. 26, 2004 Angel looks healthy and happy on the second day of a two-day sleet and snow storm. Another winter storm arrived Feb. 2, adding a half-inch of rain followed by 2 inches of snow. The ground stayed covered with ice and snow for three weeks. Overnight lows often were in the single digits.



JAN. 26, 2004 Angel's winter coat masks her true weight, but she appears heavier than she was in 2003. She had been getting lunged throughout the winter but received no work once the ice was on the ground. Angel and her buddies mostly stood around and ate hay, which turned out to have a very high sugar and starch content of 21 percent.



JAN. 26, 2004 Angel gallops in the snow. There was no indication of laminitis. On Feb. 9, Angel appeared to be off slightly in front. On Feb. 10, Dr. Don Walsh took X-rays and confirmed she had significant changes in her hooves from X-rays taken two years earlier.



FEB. 12, 2004 Angel is no longer comfortable standing by Feb. 12. She was fitted with styrofoam shoes that day to try to support her feet and lessen the pain. The styrofoam helped her move around, but, in the end, did not stop the coffin bone from rotating downward.

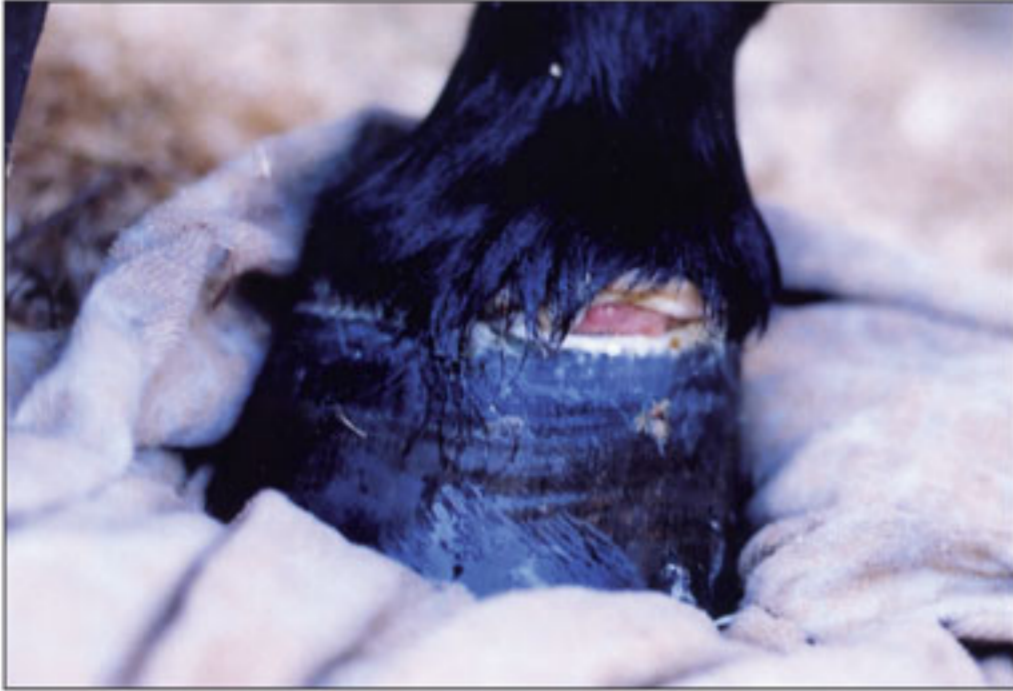

MARCH 2004 Angel stays down a lot, even with the addition of reverse shoes with heartbars on March 18. She went about six weeks with no change after that. The heartbars were removed for a day May 4, and her coffin bones cracked the soles of both feet. She was put back in the heartbars May 6.

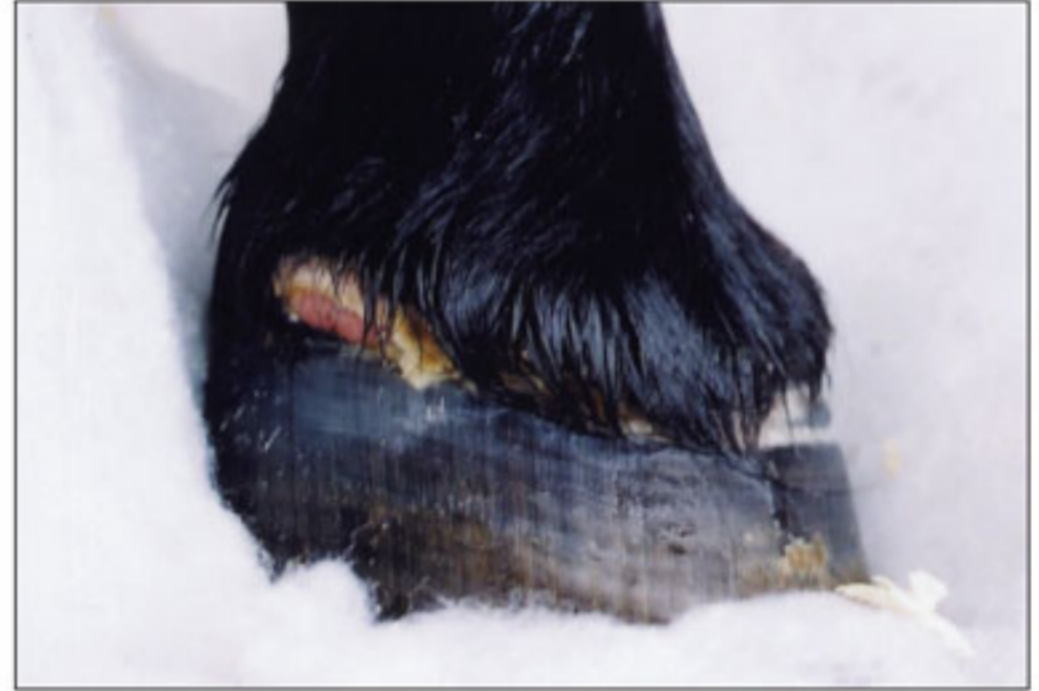

SUMMER 2004 Angel spends May, June and July getting her feet soaked for the cracked soles and for abscesses that developed at the coronary band May 31. After being soaked, her feet were wrapped in cotton for protection and cloth to allow them to breathe.

Laminitis history for Angel



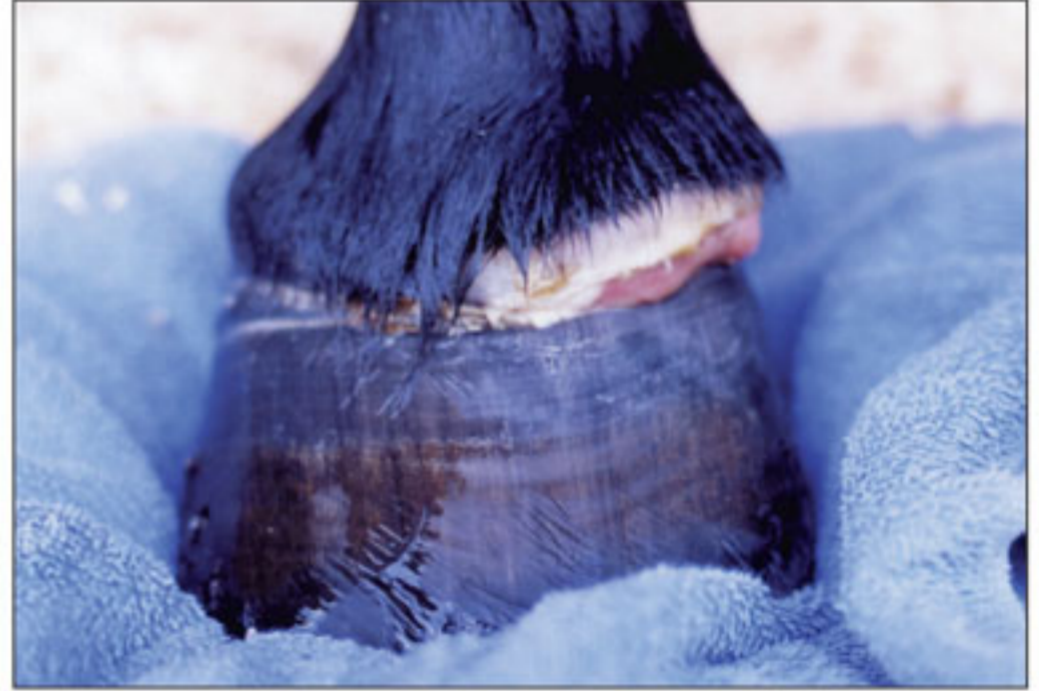JUNE 2, 2004: Angel's right hoof has an abscess on the inside wall that opened up May 31. Angel was having a lot of trouble walking and turning at this time.



JUNE 15, 2004: The abscess on the left foot has gotten bigger, as well. X-rays at this time showed some sole growth on the left hoof but very little on the right.



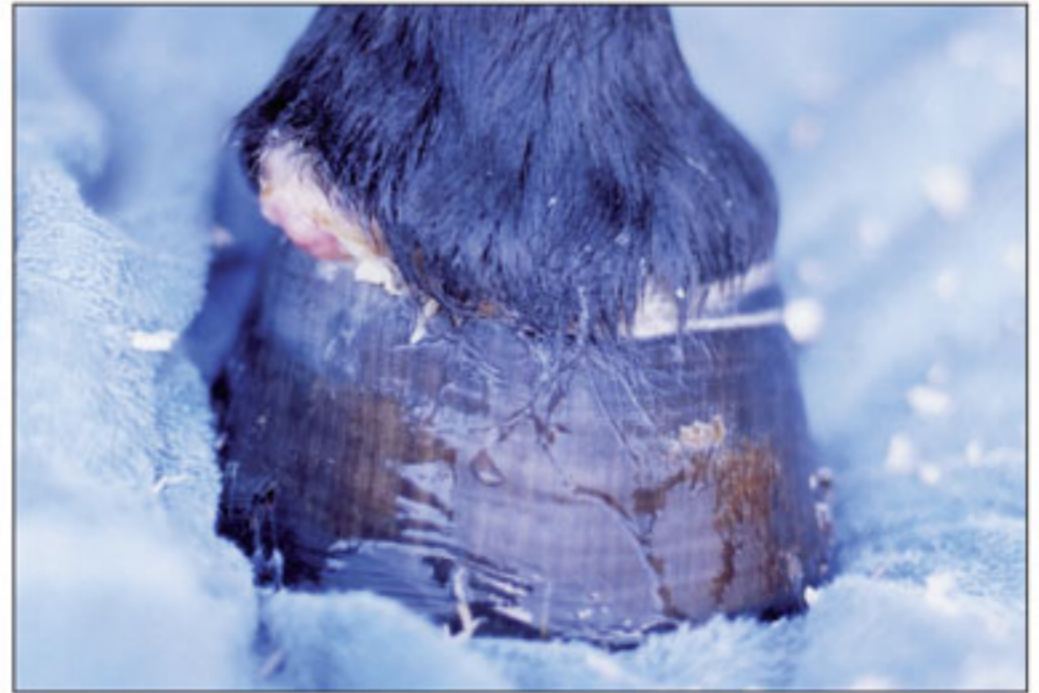JUNE 2, 2004: No photo was taken of Angel's left hoof on June 2. There was a very small abscess starting, but nothing like the right hoof. Both legs had filled in with fluid.



JUNE 22, 2004: The puffiness of Angel's coronary band on her right foot has gone down a little, but the abscess continues to drain and doesn't appear to be healing.



JUNE 15, 2004: The abscess on the right hoof has gotten much larger and continues to drain an extensive amount of dead tissue. The hoof wall has caved in a little under the abscess.

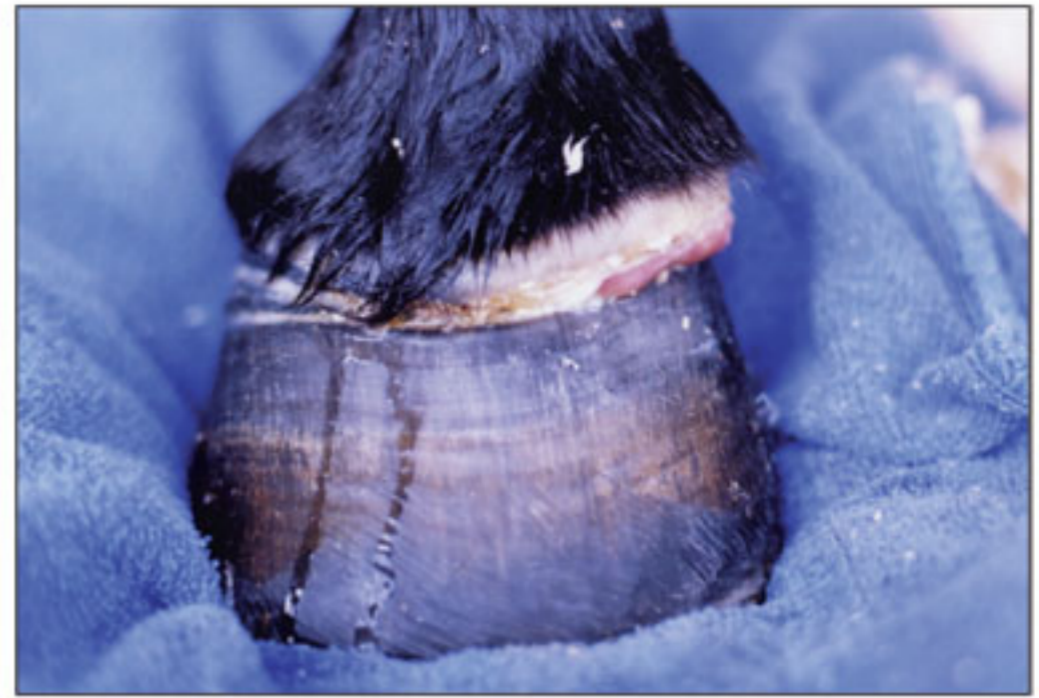


JUNE 22, 2004: The abscess on the left foot continues to spread. Angel's walking improves, but she has bad spells, when she's up on her toes and doesn't want to put her heels down.

Laminitis history for Angel



JUNE 29, 2004: Angel's feet look different after a reset of her reverse shoes on June 23. Her most recent X-rays showed her hoof collapsing to the inside, so the farrier lowered the outside wall and tried to balance her up again.



JULY 4, 2004: The abscesses are still there, but new hoof is growing above the abscesses, a good sign. Soaking continues. Angel has trouble standing on either foot for long while the other is being worked on.



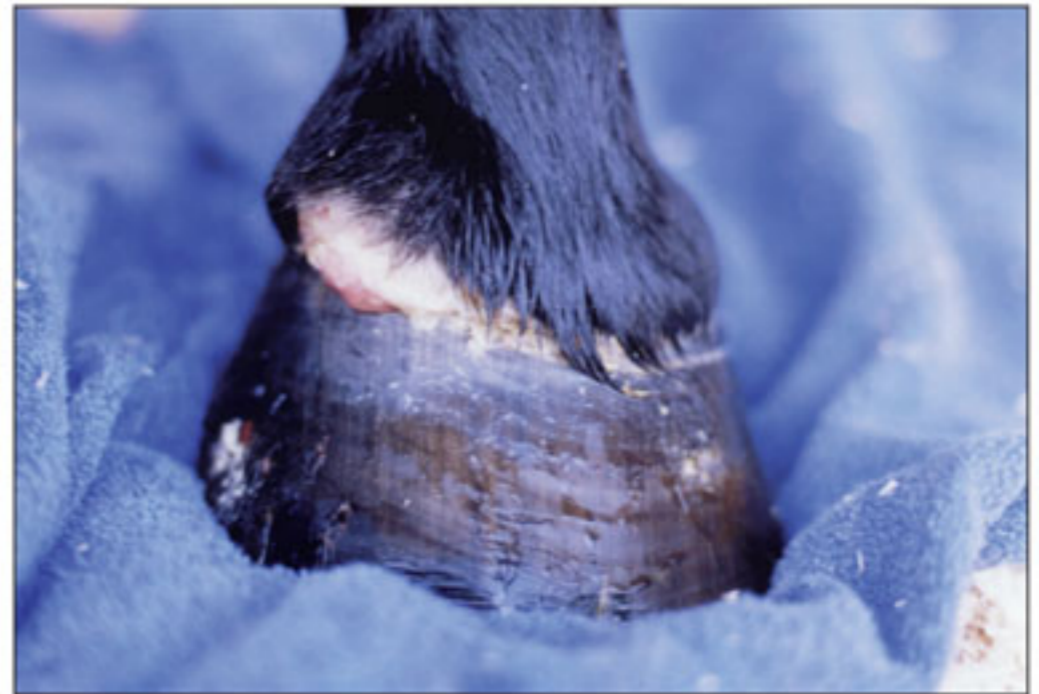JUNE 29, 2004: What may be most striking is the change in Angel's feet from a lifetime of slightly toeing out to now toeing in. Her toes are rasped off to relieve pressure and help the breakover.



JULY 4, 2004: The abscess on Angel's right foot has expanded to the back of her hoof and the separation of her hoof wall is quite visible. At this time, it does not appear that she will lose the hoof.



JUNE 29, 2004: A look at Angel's feet from a distance offers perhaps the most devastating look yet at how her hooves have been damaged by laminitis.

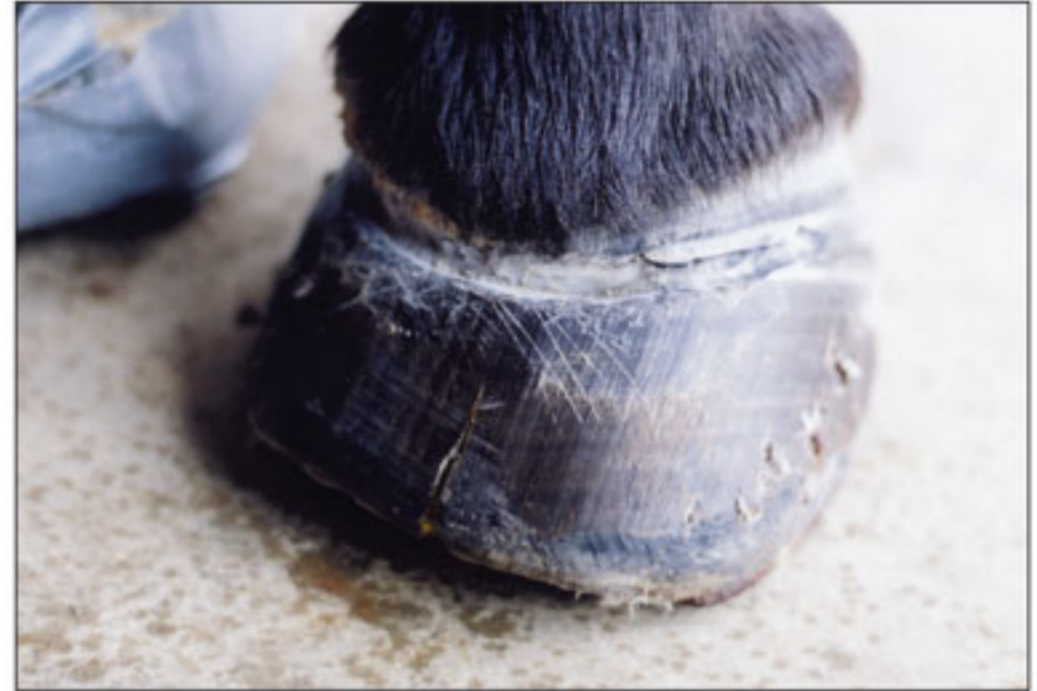

JULY 4, 2004: The abscess on the left foot has less drainage. However, the sole of this hoof has a cavern where the white line used to be. Angel is asked if she wants to go on. She says yes.

Laminitis history for Angel



AUG. 3, 2004: Angel's left hoof has little connective tissue left to stabilize the hoof wall. The stress of no support has led the front of the hoof to crack at the base and the top. The hoof felt loose to Dr. Walsh when he tested it on Aug. 3.



AUG. 3, 2004: Angel's hoof is almost finished as Dr. Walsh steps back. Eventually, the groove would go all the way through the outer surface.



AUG. 3, 2004: Dr. Walsh grooves, or makes an indentation, around the coronary band of Angel's hoof to try to relieve some of the pinching she's been feeling. With her heel growing but her toe not, Angel's hoof had become twisted.



AUG. 3, 2004: The bottom of Angel's left foot shows the bulge in the middle, where her coffin bone has been pressing on the sole, and the empty shell around the edge, where the white line should be.

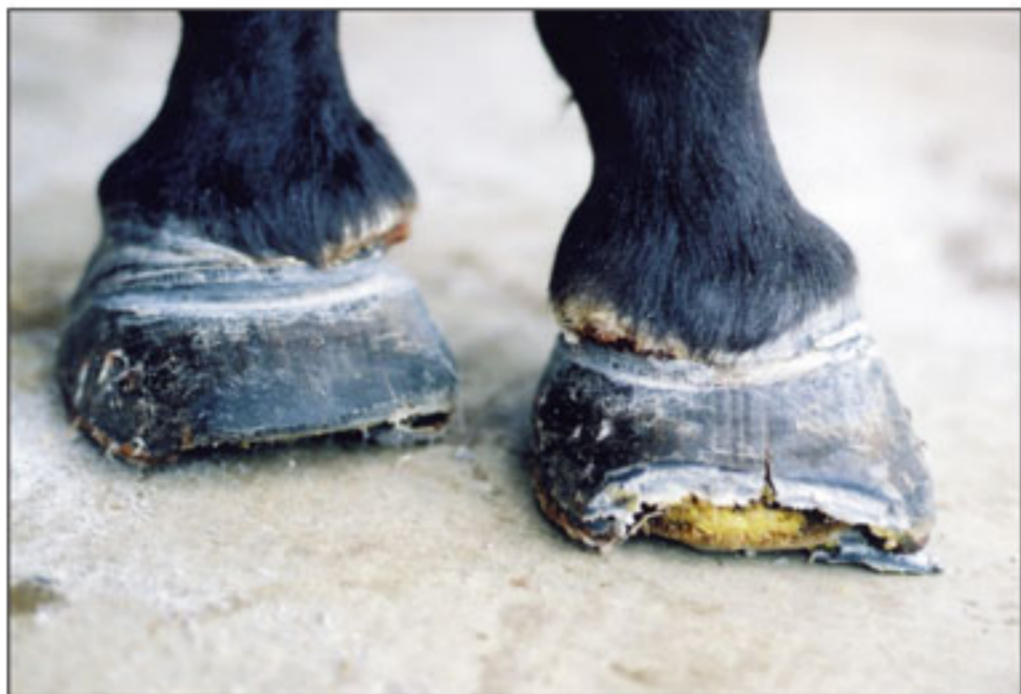

AUG. 3, 2004: Dr. Walsh continues to groove the surface. The hope was that relieving the pressure would make her more comfortable and allow circulation to return to the front of the hoof.

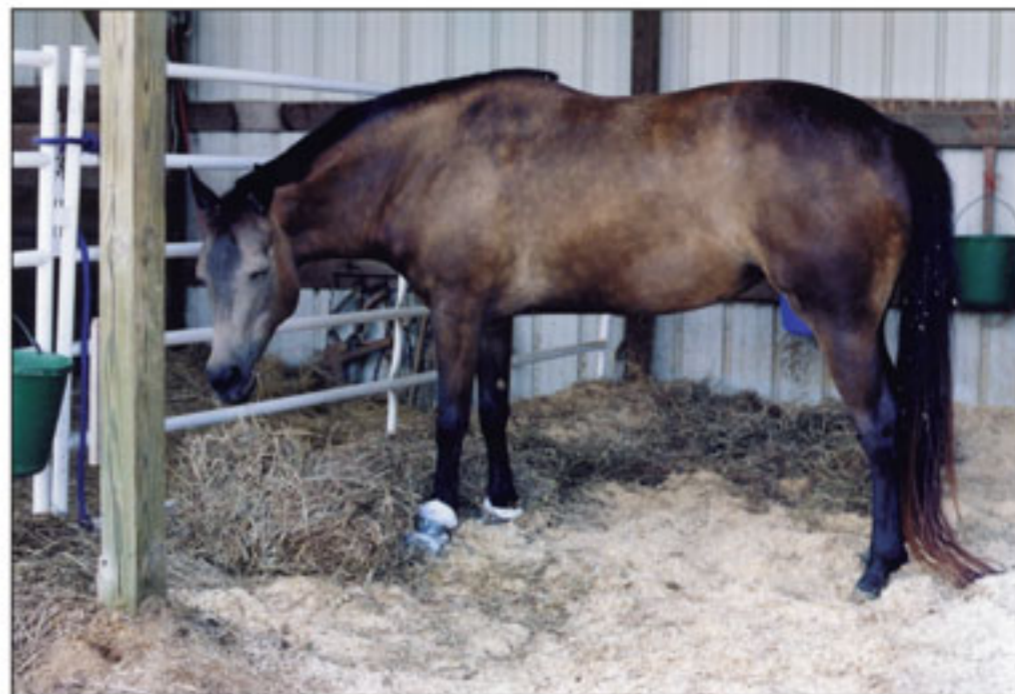

AUG. 3, 2004: Angel rests after the grooving. Her feet already appeared more comfortable than before the session started.

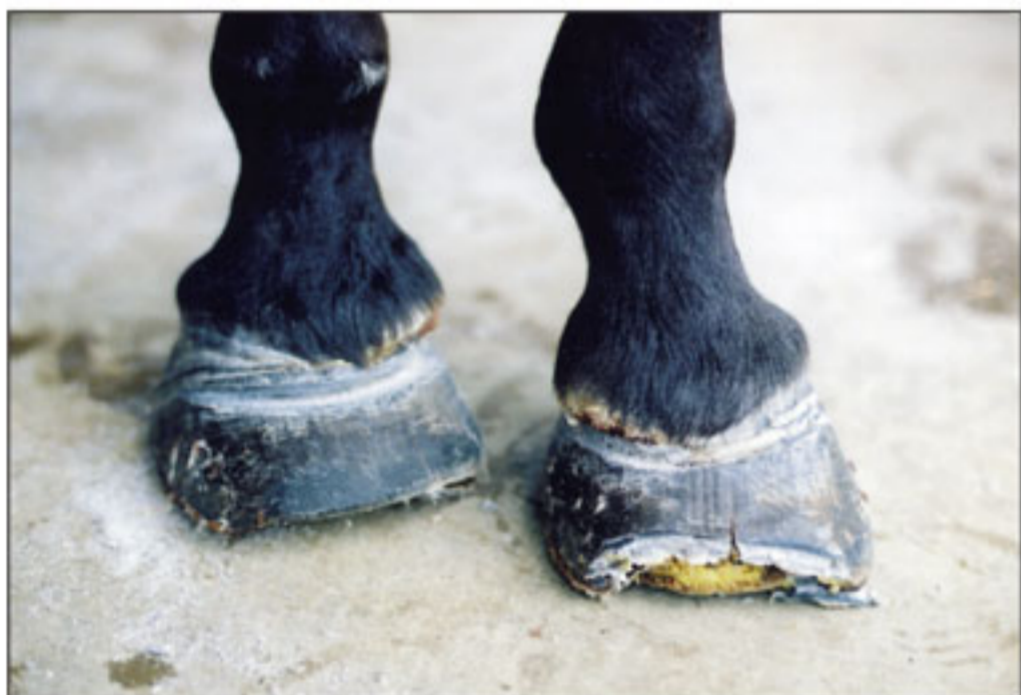Laminitis history for Angel



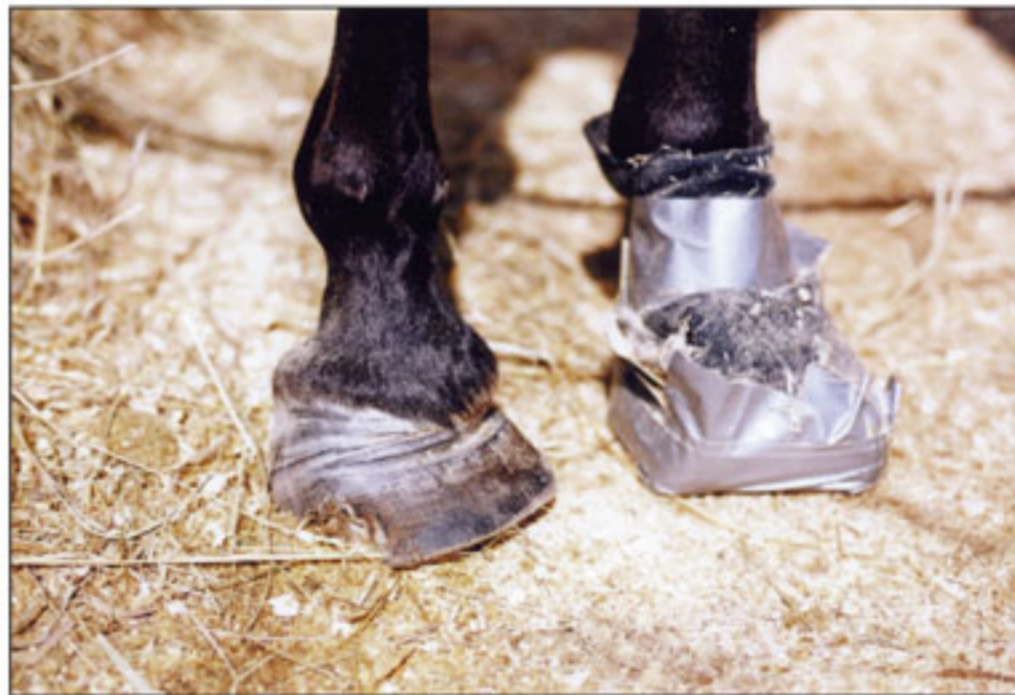AUG. 3, 2004: The lack of connective tissue in Angel's left foot is evident after the toe of the hoof is trimmed off. Again, the hope is that clearing away dead tissue will help circulation and new hoof growth. The yellow coloring is remnants of iodoform.



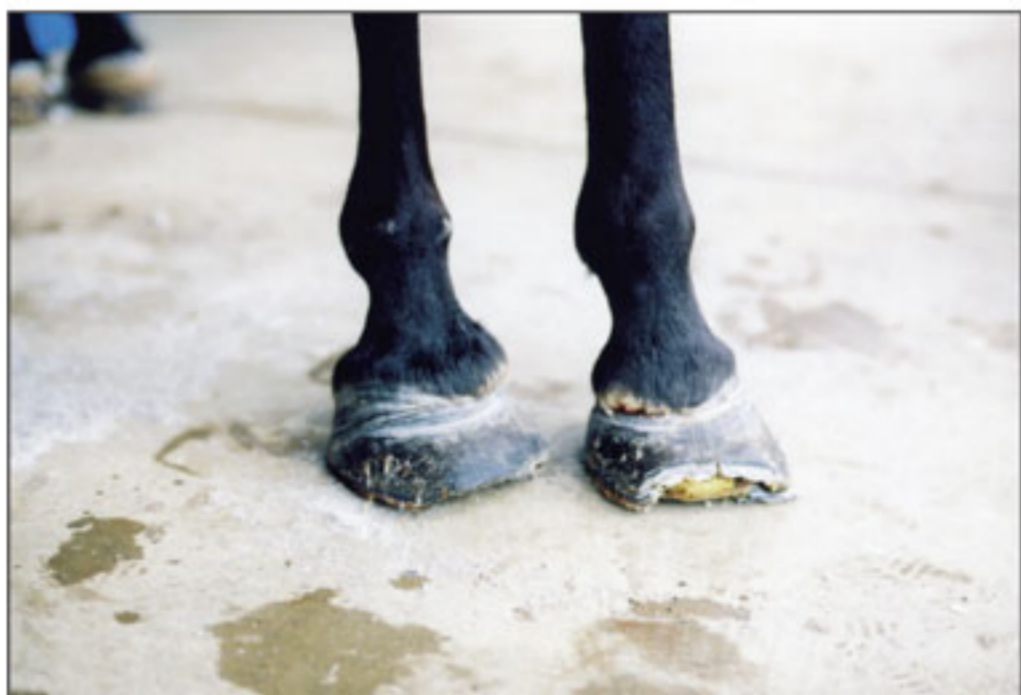AUG. 3, 2004 Angel eats hay in her room. She's been an amazingly happy patient, despite all that she's gone through.



AUG. 3, 2004: The right hoof is grooved, as well, but the hoof seems more stable and less damaged overall. In the beginning, the right foot was the one having more difficulty.



AUG. 14, 2004 Angel waits for farrier Bob Thies to arrive on a Saturday morning after losing her right shoe earlier in the week. The shoe took a large chunk of her damaged hoof with it.



AUG. 3, 2004: Angel's hooves are quite a sight. Just when you think they can't get any more interesting looking, another month passes and they've changed dramatically.

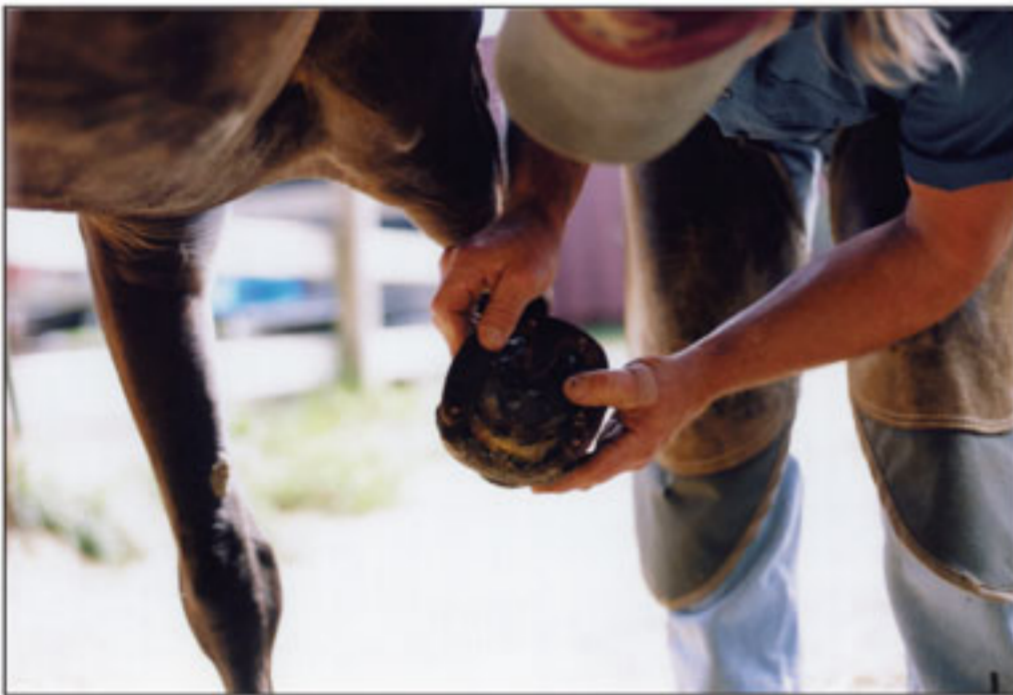

AUG. 14, 2004 There is not much left of the hoof. After seeing it, Dr. Walsh questioned whether Bob would be able to get the shoe back on. Dr. Walsh said she could go without it, since there's good keratinization around the coffin bone underneath. The outer wall has become just a shell.

Laminitis history for Angel



AUG. 14, 2004: Bob Thies says "whoa" as he sees what he has to work with on Angel's hoof. He thinks there's enough left on the heel to hammer in a few good nails.



AUG. 14, 2004: Bob fits the shoe to what's left of the hoof, commenting on the amount of white space showing through. He eventually added a little glue to the outside to fill in the hoof wall area ripped off by the shoe.



AUG. 14, 2004: Angel's hoof is back in business, even if not the most conventional looking foot. She was sore for a few days after the hammering, but six days later, she was walking on the hoof as if it felt good.



AUG. 20, 2004 Angel's left hoof has separated into an upper and lower section along the groove Dr. Walsh made Aug. 3, doing exactly what it was supposed to do. Her new hoof can grow without being pinched by the old hoof wall.



AUG. 20, 2004 The separation line allows one to see how there's no connective tissue underneath. That whole wall could come off.

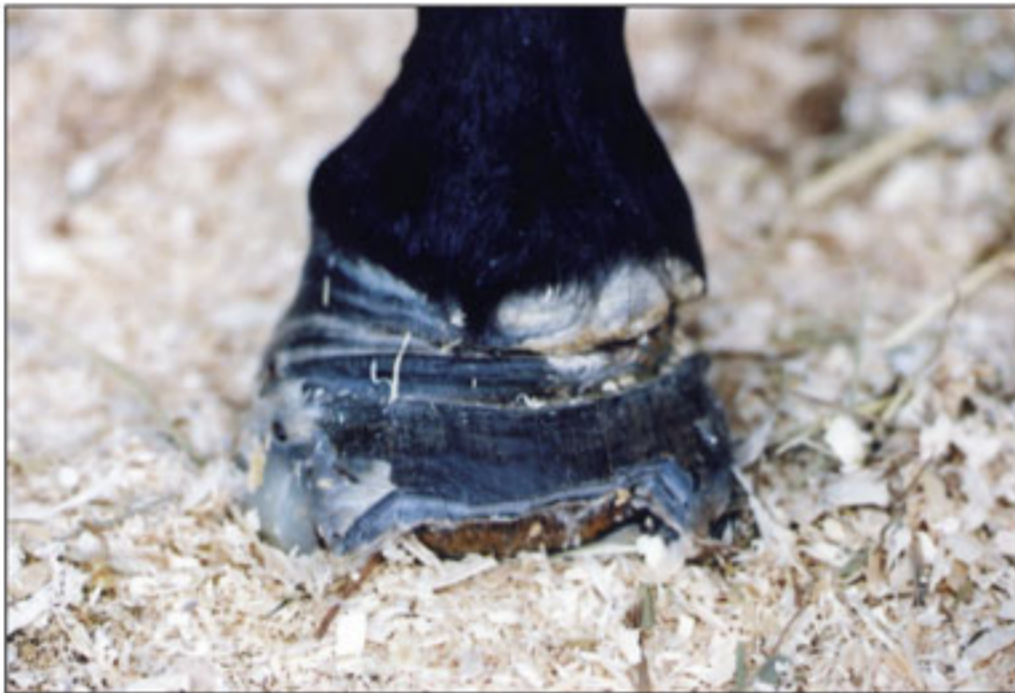

AUG. 20, 2004 Angel's feet, pathetic though they are, appear to be heading in the right direction of healing.

Laminitis history for Angel



SEPT. 13, 2004: Angel's right hoof appears more deformed, as her heel continues to grow faster than her toe. Her toe is growing, though. The option of surgery — a tenotomy of the deep digital flexor tendon — continues to be put off.



SEPT. 13, 2004: Dr. Walsh has trimmed off the toe of the right hoof since this foot was last photographed in August. The damage to the connective tissue is as bad as it is on the left hoof.



SEPT. 13, 2004: The left hoof now makes a clicking noise when the outer hoof wall is touched, sounding as if it might fall off. When Dr. Mark Cassells saw this hoof after months of being away from the case, he gasped and said, "Oh, good God."



SEPT. 13, 2004: Angel's front legs still line up correctly, but her feet now seem to be going different directions, both extensively turned in. She can get around the farm at a walk, at times moving quickly, but she slides her duct-tape covered slippers along the ground rather than picking up her feet.

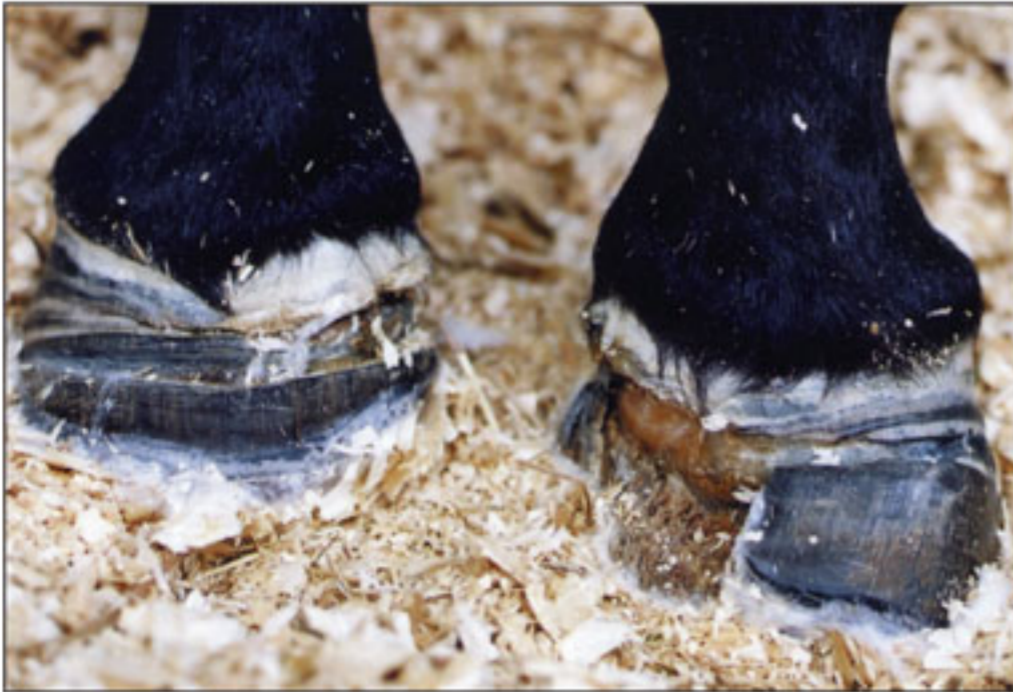

SEPT. 13, 2004 Angel continues to be a happy camper in her room, which is kept deeply bedded with shavings. Her quarters are the envy of all the other horses, especially those with chronic laminitis, who wouldn't mind having deep shavings of their own.

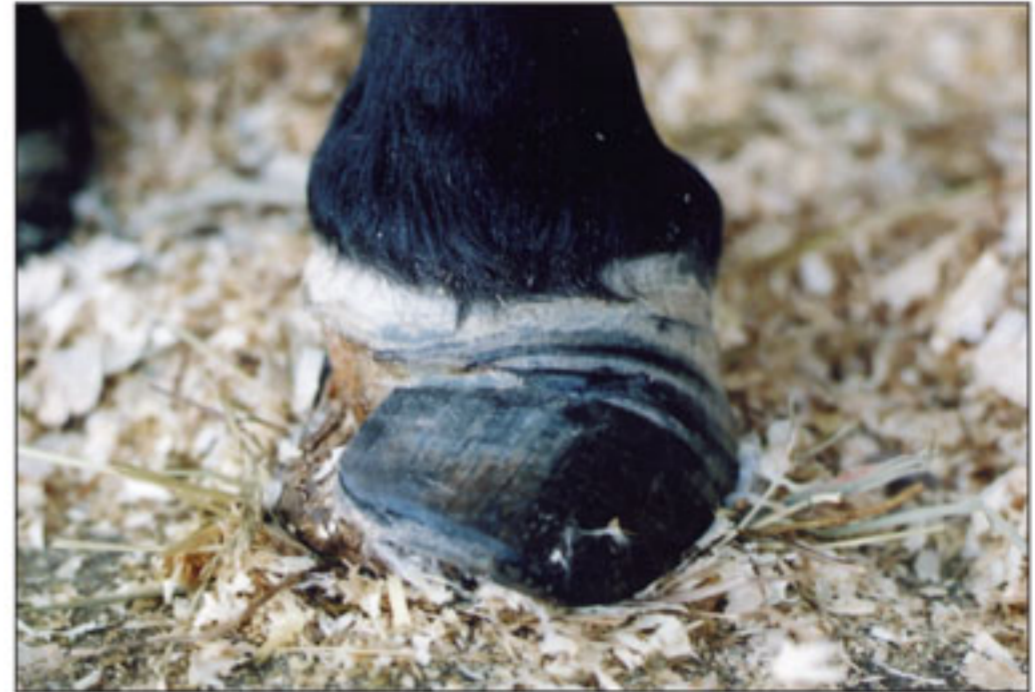

SEPT. 13, 2004: Angel, now black with her winter coat, hasn't learned anything about curbing her carbs from this whole experience. She cleans up every single piece of hay put out for her as soon as she's fed, and the amount she eats has to be watched closely and limited.

Laminitis history for Angel



SEPT. 23, 2004: Angel's left hoof is missing a chunk of hoof wall that fell off during a trimming Sept. 21. She did not have enough hoof structure left to wear shoes anymore. Her feet continued to be wrapped in cotton, fleece and duct tape. Her soundness improved over the next few weeks without the shoes.



OCT. 17, 2004: A closer look at the left hoof from the same angle shows the devastation to the symmetry. It also shows the new growth taking place near the heel.



OCT. 17, 2004: Angel's new hoof growth at the coronary band is more evident, although some days it feels as if that new hoof will never make it down to the ground.



OCT. 31, 2004 Both of Angel's feet are showing more new growth at the top. Her hooves seem to be growing faster now. She has galloped several times in recent weeks, inspired by the cold weather and apparently more comfortable on her feet.



OCT. 17, 2004: Angel's left hoof looks quite deformed when seen from this angle, thanks to the missing hoof wall and the heel continuing to outpace the front of the hoof in growth. Again, only time will tell how much this hoof can heal.

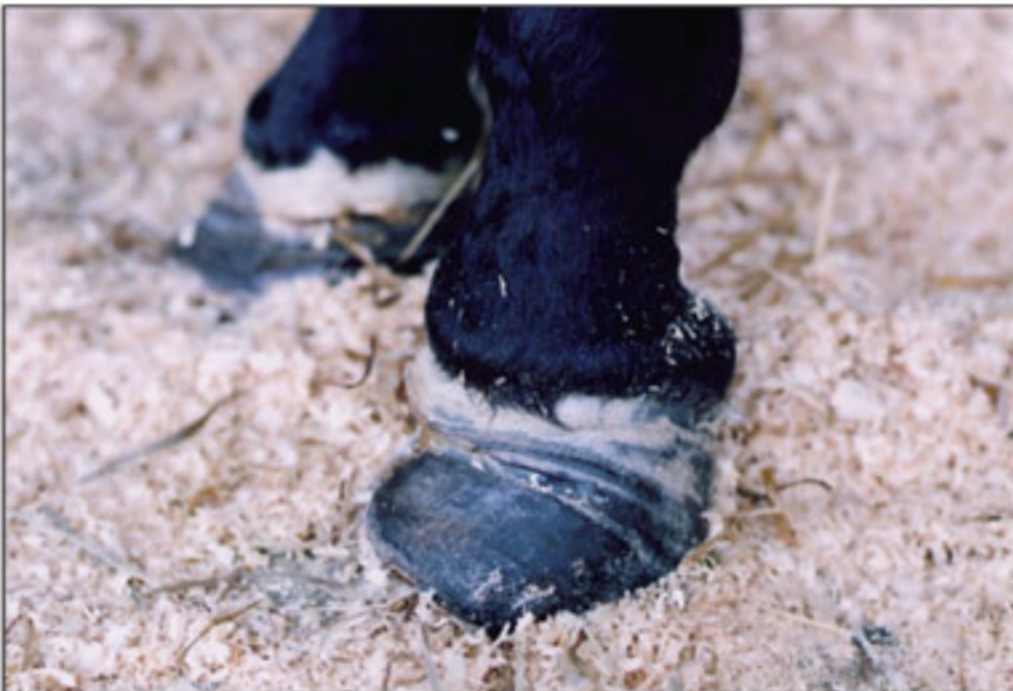

OCT. 31, 2004: The hoof walls of Angel's feet have months to go before looking more normal, but, thankfully, the soles healed well during the summer, and Angel is comfortable moving around on them. She has been off bute for about a month.

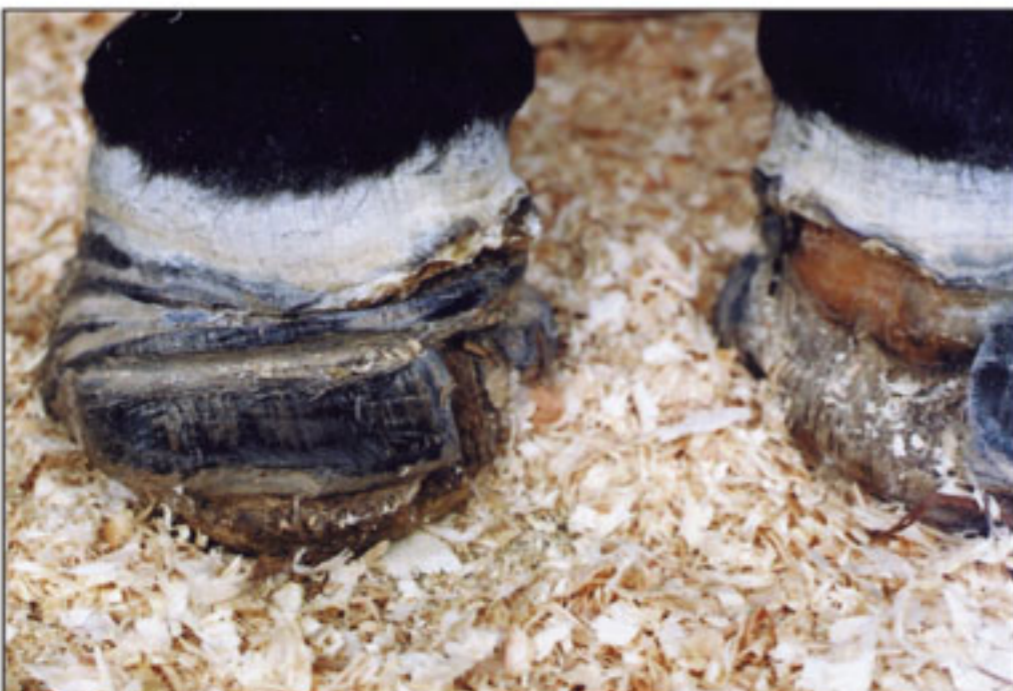Laminitis history for Angel



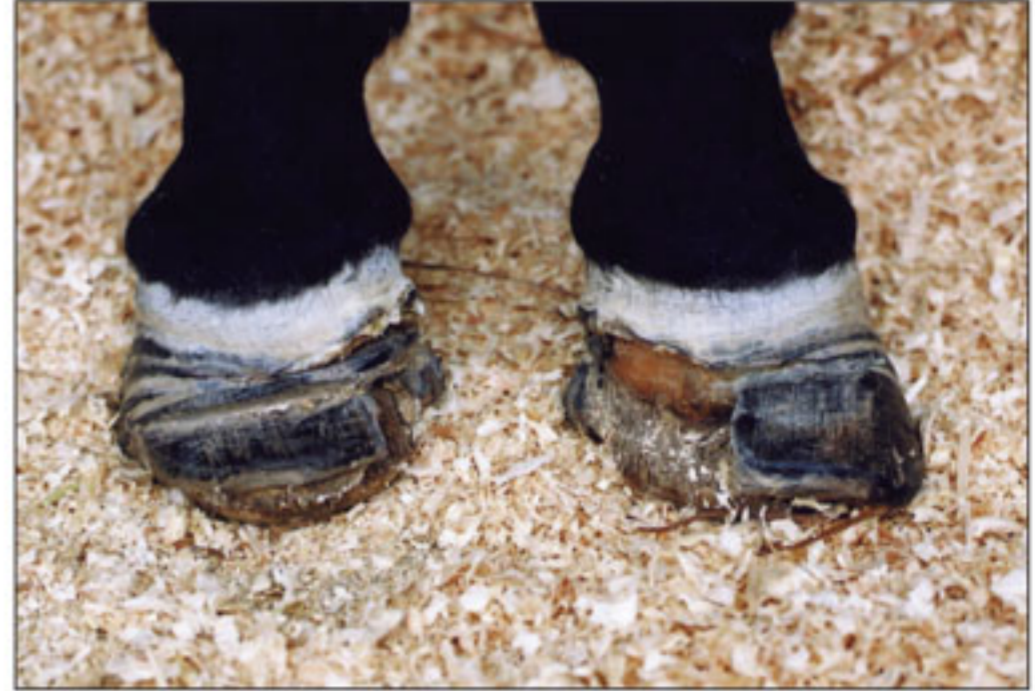OCT. 31, 2004: Another closeup of Angel's left hoof shows the crumbling wall has remained the same for the past two weeks, rather than getting worse.



OCT. 31, 2004: Angel's hoof appears to be growing two directions, because the groove created by Dr. Walsh in August has allowed the stretched toe to keep going forward, while the new, healthy wall is growing down.



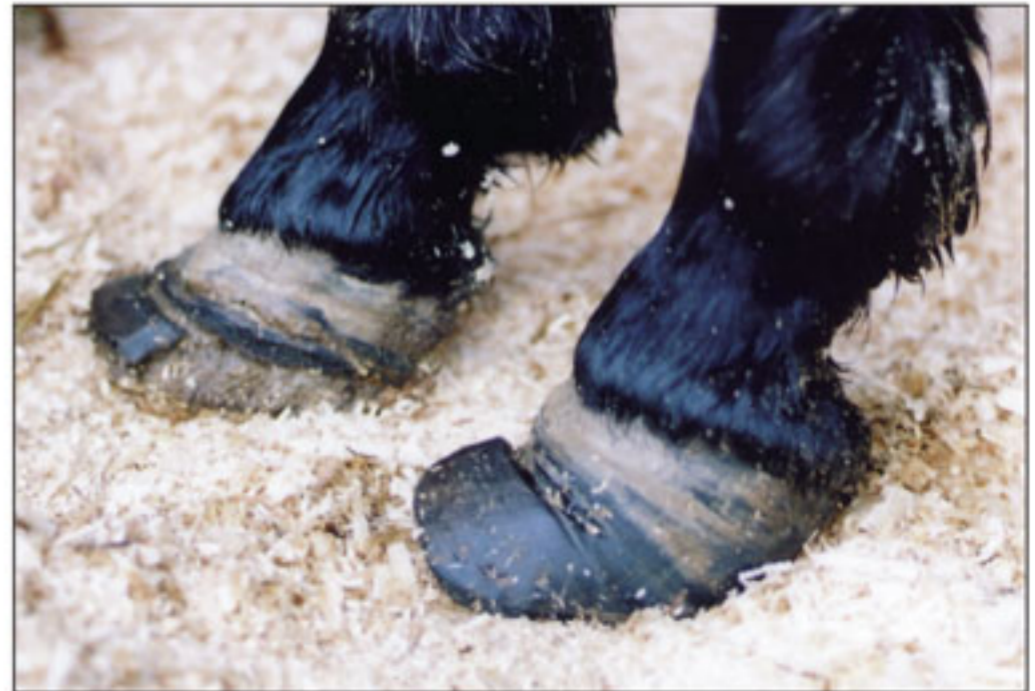NOV. 14, 2004: Angel's right hoof has lost a chunk of inside wall, similar to that lost by the left one in September. It does not seem to bother her. The coffin bone is covered with a keratinized layer, and she doesn't appear to notice the exposed area.



NOV. 14, 2004: Both hooves are the sum of two processes: the bottom half, made up of the twisted, stretched hoof damaged by laminitis, and the fairly normal looking upper half, created by her chemistry seemingly being in balance during the summer and fall.



NOV. 23, 2004: Angel's feet are once again lined up straight, or even towed out a little, which is normal for her, after months of towing in. No one noticed it happening. The hooves just straightened out. They also are growing even faster.



NOV. 23, 2004: Angel no longer is wearing her protective cotton slippers. Fall brought so much rain that it was impossible to keep her feet dry. The wet cotton was making her hooves mushy and unhealthy. The cotton was removed Nov. 22. After 24 hours without them, Angel appeared to be doing fine.

Laminitis history for Angel



DEC. 4, 2004: Angel's feet look more normal in shape this week. Dr. Walsh pulled off the excess hoof wall pieces from the toes on Nov. 30, reducing the lumpiness on the front of the hooves.



DEC. 4, 2004: Angel's feet look comfortable and balanced, as the new growth comes in. She still needs to stay on shavings when she's standing around. The longer she is on hard ground, such as when she's with the other horses in the paddock, the more she starts to shift her weight from one leg to the other.



DEC. 4, 2004: Angel's left hoof appears chipped up, but both hooves are in good condition, according to Dr. Walsh. He removed the excess from the toes because he was concerned about mud getting lodged into the crevices under the damaged wall.



DEC. 4, 2004: Angel's feet look much better from the right side without the ski-jump-shaped toes. While the dead wall provided protection, it was not a pretty sight.



DEC. 4, 2004: Angel's right hoof looks a little better than the left, although she's not favoring either foot at this time. She can trot and canter with gusto in the sand and on grass. Continual rain has prevented her from getting too much turnout time.



DEC. 4, 2004: The profile from the left side looks equally improved.

Laminitis history for Angel



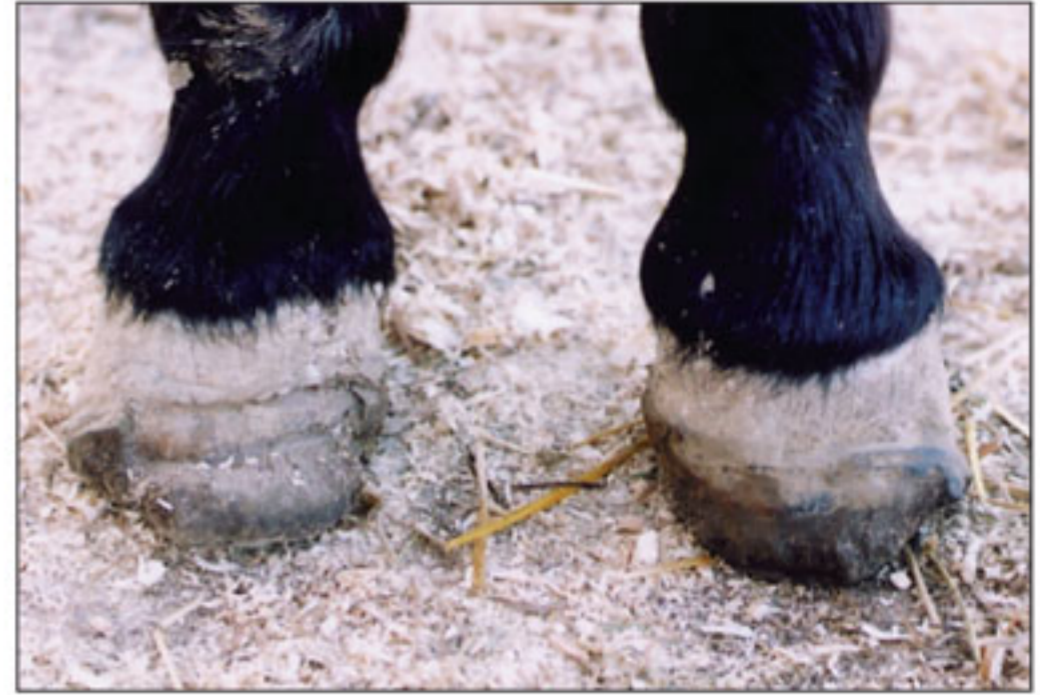DEC. 4, 2004: The bottom of Angel's right hoof gives a scare because the frog is mushy and the edges look so broken up. However, Dr. Walsh cleaned up the soles Dec. 7 and said they look good.



DEC. 4, 2004: Angel's left hoof looks worse from the bottom with some of the damaged toe removed. But, Dr. Walsh noted in his visit Dec. 7 that the soles are continuing to "cup" well (return to their concave shape), and he was pleased with the progress.



DEC. 26, 2004: Angel leans against a post in the herd's paddock, while all the horses run loose on the upper half of the property. Angel is aware of her limitations and keeps her distance from the other horses when they're really frisky, but she still wants to be part of the group.



DEC. 26, 2004 Angel's feet look as if they're returning to a fairly normal shape. More damaged toe was removed by Dr. Walsh on Dec. 21. Angel has two levels of soundness now: Her feet hurt when she walks on the frozen dirt; but when on softer footing, she trots, gallops and bucks like she's in no pain.



DEC. 26, 2004 The large chunk of damaged toe on the left hoof is gone, leaving Angel with no interesting bumps. Still, she's several months away from the new hoof growth reaching the ground.



DEC. 26, 2004 The right hoof still has some damaged toe that needs to come off before it catches up with the left in looking more normal.

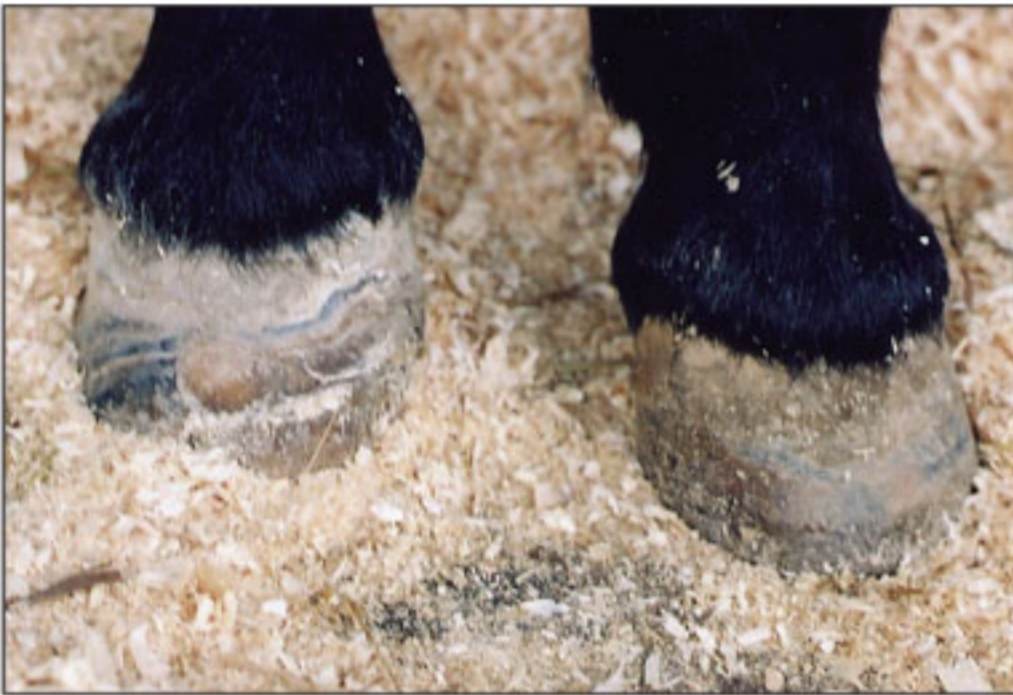Laminitis history for Angel



JAN. 15, 2005: Angel is reaching the anniversary of her ordeal and remains upbeat, despite having been locked up for a year — her least favorite thing. She has surprised everyone, both in the severity of her case, and in how well she managed to recover. She has not complained once.



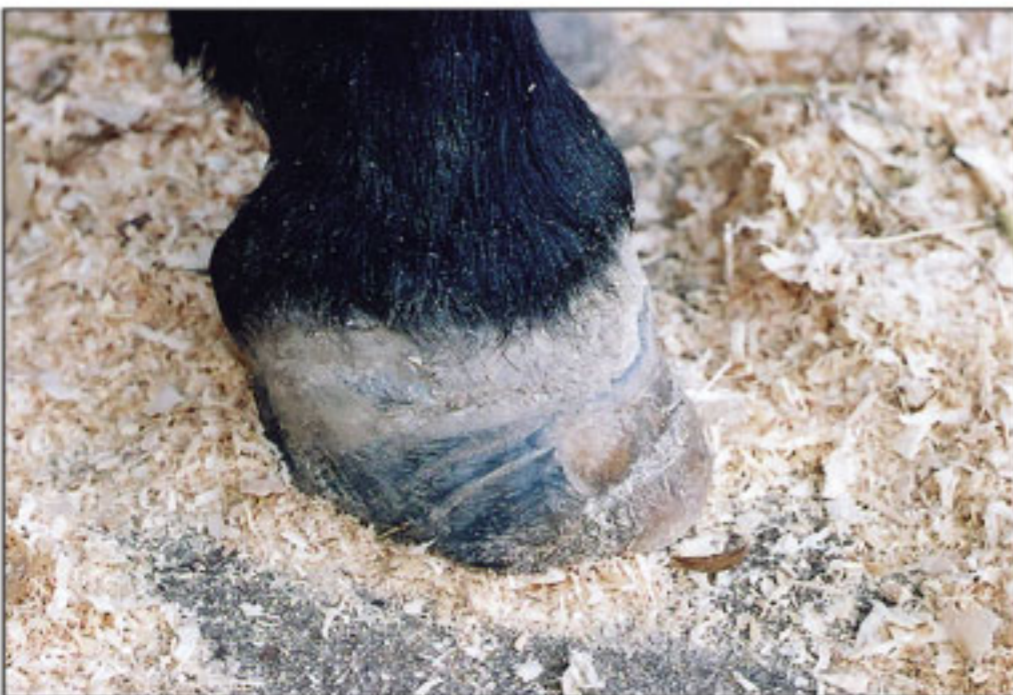JAN. 15, 2005 Angel needs less shavings to stand on at this point and rarely lies down, preferring mostly to sleep on her feet.



JAN. 15, 2005: Angel's feet look even more improved, thanks to farrier Bob Thies trimming off the last of the lumps on the right hoof on Jan. 14. A wet and cold winter has not caused any setbacks in Angel's improvement.



JAN. 15, 2005 The bottom of Angel's left hoof has returned to a much more healthy surface with a normal concave shape. The huge bulge where her coffin bone was pressing on her sole is gone.



JAN. 15, 2005: Angel's feet remain comfortable without her cotton slippers, even though the temperature has dropped to near zero recently. She still has trouble walking on frozen ground, though, and mostly stays in her room.



JAN. 15, 2005 The right hoof also looks healthy and concave. Angel already has reached a level of soundness that is surprising. How much she continues to improve is as much of a mystery as this entire case of laminitis.

